

Cardiovascular System: Blood Vessels and Circulatory Routes (Ch. 21)

Human Anatomy lecture

(Read the historical background on p. 596)

I. Vessel wall (Fig. 21.1)

- ① tunica interna (intima) –
- ② tunica media --
--
- ③ tunica externa (adventitia) –

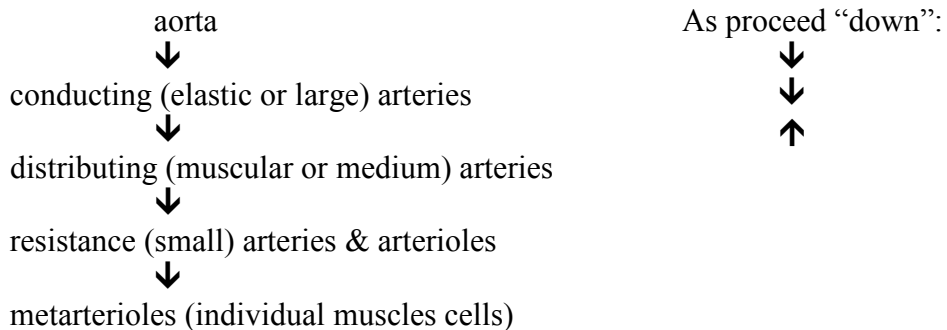
II. Arteries (resistance vessels)

A. Specializations

- 1. elastic -- allows rebound and maintains blood pressure
 - ↳ internal elastic lamina --
 - ↳ external elastic lamina --

- 2. contractile = vasomotion →
 - ↳ vasodilation
 - ↳ vasoconstriction

B. Branching Pattern



III. Capillaries (microcirculation) → function as exchange vessels

A. General structure

- tunica interna only
-

B. 3 types (KNOW Fig. 21.5, 6, & 7)

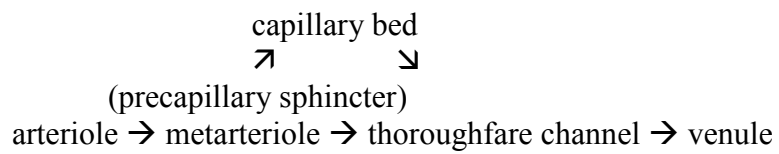
- ① continuous -- most common
 -
 -

- ② fenestrated -- kidney, small intestine
-

③ sinusoids (discontinuous) – liver, bone marrow & spleen

--

C. Branching pattern of microcirculation (**KNOW Fig. 21.9**):



-sketch-

IV. Veins (capacitance vessels = *blood reservoirs*, containing 60% of body's blood)

A. postcapillary venules

-

-

B. muscular venules

-

-

C. medium veins

-

-

-

D. Venous sinuses

-

-

E. Large veins

V. Circulatory routes (KNOW Fig. 21.12)

-- **anastomoses** - allow collateral circulation

--

--

VI. Pulmonary circulation

- review heart

-

VII. Systemic circulation

A. Arteries

-sketch-

visceral branches →

parietal branches →

B. Veins

- deep veins typically accompany artery with same name
- in the limbs, arteries often have paired veins
- pattern is highly variable
- anastomoses more common

Note: azygos system is an important by-pass of the superior & inferior vena cavae

-sketch-

VIII. Special circulations

A. Hepatic portal circulation → Fig. 21.26

portal system → carries blood between two capillary networks

-- Sketch --

-hepatic portal system - transports absorbed nutrients directly to the liver for processing

→ SEE HANDOUT

B. Coronary Circulation

- review heart
- NOTE: Coronary arteries first branch off ascending aorta: the heart gets the “best” blood

C. Cerebral circulation – Fig. 21.18

- cerebral arterial circle - (Circle of Willis)
- complete (? 20%!) ring of interconnected arteries to insure brain’s supply
- 4 arteries provide redundant supply to the circle

-sketch-

D. Fetal circulation - **Fig. 21.37 & 20.18**

1. Designed to
 - deliver blood to placenta for gas/nutrient exchange
 - bypass nonfunctioning fetal lungs/gut
 - rapidly shift to adult pattern at birth

-sketch-

Note: no physical mixing of blood

Details: **See Handout**

-- compare with Fig. 15.17

2. At birth: must instantly shut down all bypasses and establish adult pattern.

- smooth muscle constriction closes by-pass vessels

- increased blood flow to lungs



increased return to left atrium



pushes flap



closes foramen ovale → becomes fossa ovalis

KNOW: 5 “remnants” **Fig. 21.37**